

Diagnosis and Management of HPV-Associated Anogenital Dysplasia in HIV-Infected Men and Women

Joel Palefsky, MD, FRCP(c)
Professor of Medicine
University of California
San Francisco
San Francisco, California

SUMMARY BY TIM HORN
EDITED BY
STEPHEN E. GOLDSTONE, MD, FACS,
AND ANTONIO URBINA, MD

Reprinted from *The PRN Notebook*® | JUNE 2004 | Dr. James F. Braun, Editor-in-Chief | Tim Horn, Executive Editor.
Published in New York City by the Physicians' Research Network, Inc.® | John Graham Brown, Executive Director
For further information and other articles available online, visit [HTTP://WWW.PRN.ORG](http://www.prn.org) | All rights reserved. ©JUNE 2004

ANTIRETROVIRAL THERAPY CONTINUES TO HAVE A POSITIVE IMPACT ON both the incidence and prevalence of many AIDS-related diseases. At the same time, the life-extending benefits of antiretroviral therapy have paved the way for infections with long latency periods to fulfill their pathogenic potential and culminate into life-threatening complications. A prime example of this is human papillomavirus (HPV) and its sinister sequelae: squamous intraepithelial lesions and invasive cervical or anal carcinoma.

For clinicians involved in the management of HIV-infected individuals, HPV infection is proving to be a significant challenge. This article reviews the epidemiology, pathogenesis, diagnosis, monitoring, and management of cervical and anal dysplasia in the setting of HIV. "Data continue to emerge, supporting the diagnosis and management of cervical and anal dysplasia in HIV-infected patients," said Dr. Joel Palefsky, who returned to PRN in April 2004 to discuss recent advances in the study and clinical care of HIV/HPV coinfection.

I. HPV Primer

Human Papillomavirus (HPV)

HUMAN PAPILLOMAVIRUS (HPV) IS THE MOST COMMON SEXUALLY TRANSMITTED agent. It is more common than herpes and chlamydia and it has been estimated that more than 75% of sexually active adolescents and adults, between the ages of 15 and 49, acquire at least one type of HPV infection during their lifetime.

"The way that patients know they have HPV infection is primarily through genital warts," Dr. Palefsky explained. "Very often, it's the patient who brings these warts to the attention of his or her doctor. They can feel them. They burn and they itch. But these patients with warts represent the tip of the HPV iceberg. The majority of patients with HPV have subclinical infection that can only be found doing a Pap smear, a visual inspection, or have evidence of HPV-DNA in their genital tract but no signs of disease."

More than 200 different HPV genotypes exist, approximately 30 of which infect genital mucosal tissues. These include nononcogenic varieties—primarily types 6 and 11, as well as types 42, 43, and 44—that are associated with the development of genital condylomas or mild dysplasia (along with plantar and palmar warts) and generally do not progress to either higher-grade lesions or cancer. Oncogenic varieties—types 16, 18, 31, and 35—are associated with more dysplastic lesions and account for the majority of invasive cervical or anal carcinoma cases. HPV type 16 accounts for approximately 50% of all cervical cancers; types 18, 31, and 35 account for an additional 20%; types 39, 45, 51, 52, 56, 58, 70, and others likely account for the rest.

Infection of the Cervix and Anus

HPV INFECTION INITIALLY TAKES PLACE AT THE BASAL CELL LAYER OF THE anogenital epithelium. "This is the replicating cell layer," Dr. Palefsky said. "When the cells divide they carry copies of the virus with them. One of the clinical consequences of this is the potential to generate a permanent or semi-permanent infection, given that these cells are basically immortal and end up maintaining a permanent reservoir for HPV in the epithelium."

In the cervix, HPV infection usually occurs in the transformation zone or squamocolumnar junction, where the columnar epithelium of the endocervix meets the squamous epithelium of the exocervix. In the anal canal, HPV infection also occurs in the transformation zone, located at the junction of the stratified squamous epithelium of the anus with the columnar epithelium of the rectum. Cervical and anal epithelia are histologically very similar and the transformation zone is typically the place where most HPV-associated lesions, including invasive carcinoma, develop.

Several classification systems have been used for the purpose of grading the cellular atypia seen in HPV lesions, varying from relatively benign lesions to invasive malignant neoplasms. The Bethesda system is the accepted standard for classifying and staging cytology for both cervical and anal precancerous lesions (ASC, 2003).

At one end of the HPV disease spectrum are anogenital warts (condyloma acuminatum) and mild dysplasia: cervical intraepithelial neoplasia grade 1 (CIN I) and anal intraepithelial neoplasia grade 1 (AIN I) (see Figure 1). The Bethesda system combines CIN I and AIN I into one single category: low-grade squamous intraepithelial lesions (LSIL). "The good news about LSIL is that, while it's very common, it regresses spontaneously most of the time," Dr. Palefsky added. "It is not considered to be a cancer precursor."

At the other end of the spectrum are CIN/AIN grades 2 and 3—also known as moderate and severe dysplasia, respectively—and carcinoma *in situ*. The Bethesda system groups all these changes as high-grade squamous intraepithelial lesions (HSIL). Another cytological classification is that of atypical squamous cells of undetermined significance (ASCUS), which refers to cells that cannot be classified as either completely normal or dysplastic. "The good news about HSIL is that, since it takes a long time for them to progress to invasive cancer, we have multiple opportunities to interfere with the process," Dr. Palefsky said. "The whole basis of the Pap smear screening system and cancer prevention screening system is to detect and treat this lesion before progression to cancer can actually occur."

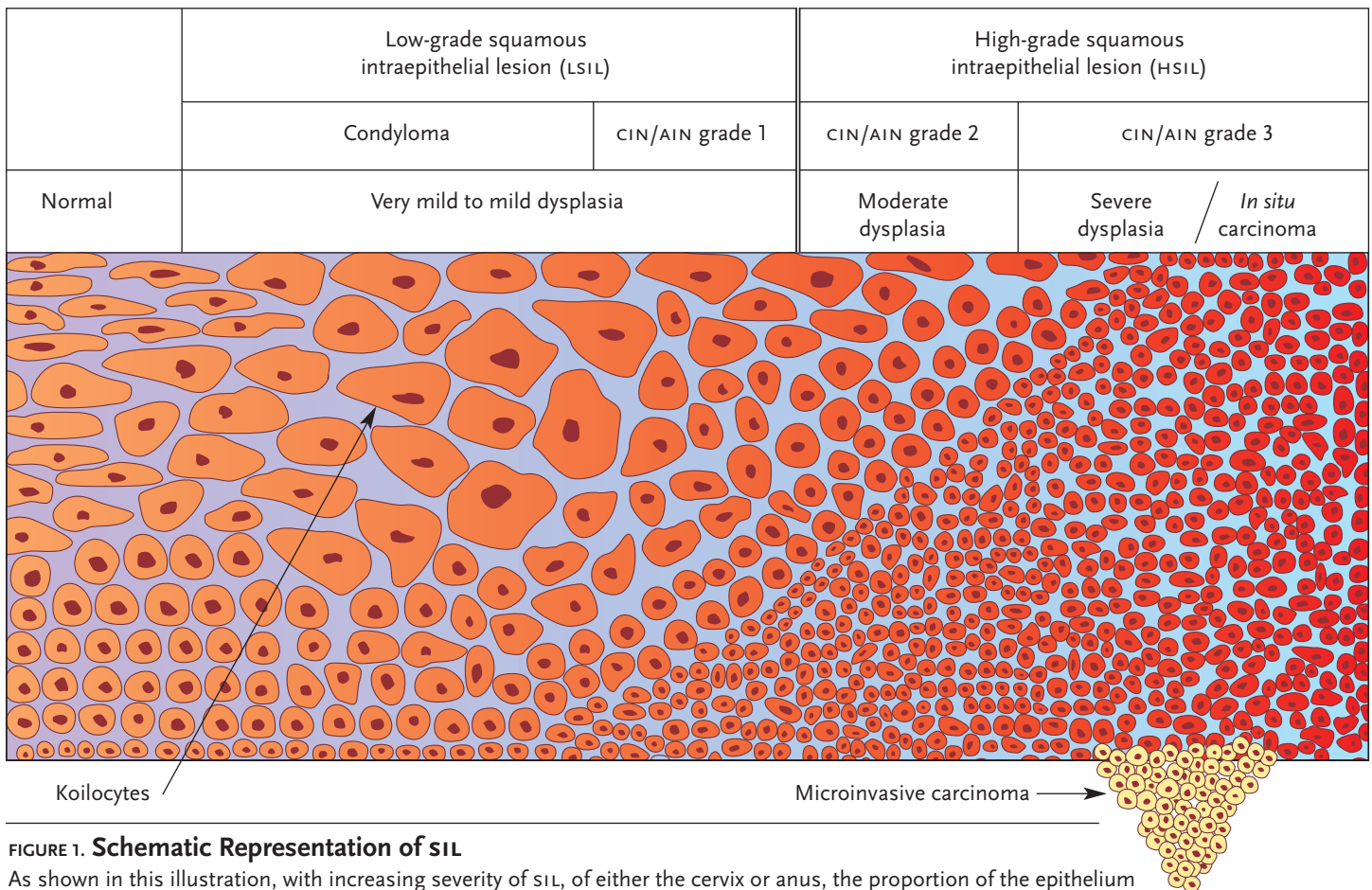


FIGURE 1. Schematic Representation of SIL

As shown in this illustration, with increasing severity of SIL, of either the cervix or anus, the proportion of the epithelium replaced by immature cells with large nuclear-cytoplasmic ratios increases. Invasive cancer probably arises from one or more foci of high-grade SIL (HSIL), as depicted in the drawing by epithelial cells crossing the basement membrane below the region of HSIL.

Source: Joel Palefsky, MD, FRCP(C)

II. Cervical Dysplasia and Carcinoma

General Screening Issues

SINCE ITS CLINICAL DEBUT IN THE 1940S, PAPANICOLAOU (PAP) SMEAR testing has been the gold standard for cytologic screening of the cervix. Although the false-negative rate of Pap smears in the general population has been reported to be as high as 20% to 45%—one-half of the false negatives are likely because of inadequate specimen sampling and the other half are attributed to failure to identify the abnormal cells or to interpret them accurately—its role in reducing the rates of cervical cancer over the past 50 to 60 years is undisputed. Prior to the introduction of Pap smears, the incidence of cervical cancer was 40-50/100,000 women. More recent data show that the incidence in the United States is approximately 8/100,000 women—a marked improvement—indicating that cervical cancer is, by and large, completely avoidable.

“The fact is,” Dr. Palefsky said, “a single Pap smear is a very bad screening test. Approximately half of the Pap smears from women with cervical abnormalities will come back normal. The good news is that its cumulative sensitivity is okay. The reason that it works as well as it does is because we tell women to come back. With repeated testing, the chances that we’ll find an abnormality before it progresses to cancer are good. Not all of the time, unfortunately, but most of the time.”

Pap smears that suggest abnormal cells require further evaluation by colposcopy, colposcopic-directed biopsy, and sometimes endocervical curettage. Colposcopy offers direct visualization of the cervix with an

opportunity to biopsy sites of abnormality, and the results can be clinically correlated—by assessing characteristic color changes, vascular patterns, and margins—with the results of the Pap smear. Colposcopy-directed biopsy usually provides enough clinical evidence for an accurate diagnosis. If colposcopic evaluation is unsatisfactory or inconclusive, a cervical conization biopsy may be required, performed by a loop electrical excision procedure (LEEP), laser, or cold knife.

Risk Factors

ALTHOUGH HPV INFECTION IS THE MOST SIGNIFICANT RISK FACTOR ASSOCIATED with the development of anogenital dysplasia and carcinoma, it is not the only one. Age is also of importance. “When women are pubertal, the transformation zone is immature, bigger, and more exposed,” Dr. Palefsky commented. “Not only does this place them at a higher risk for other sexually transmitted infections, like chlamydia, it also appears to increase their risk for getting HPV.” There is also cigarette smoking. “HPV causes lesions, not so much through a direct effect, but rather through chromosomal instability in cells,” he said. “You can imagine that in a woman who smokes, there is an increased risk of ongoing genetic damage. We’ve seen studies showing that women who smoke have higher levels of tar and nicotine in their cervical mucus than in their serum.”

Immune suppression is a significant risk factor. “We know that many women are infected with HPV in their lifetimes but only a few of them experience dysplasia,” Dr. Palefsky explained. “Something is

protecting a number of women. It is believed that the majority of women are protected by a cell-mediated immune response that controls HPV infection, the nature of which is not very well understood. Women who lose their immune competence might be at an increased risk of disease. We know this from historical experience.” For example, women undergoing renal transplants or people who have been iatrogenically immune suppressed have a fivefold to a 100-fold increase in the risk of cancer of the vulva and cervix, compared with age-matched women.

Genetic factors, independent of immune suppression, can also play a role in cell-mediated immune responses to HPV infection. There are some data to suggest that the major histocompatibility complex (MHC) haplotypes are associated with an increased risk of dysplasia and cancer or, in some cases, a decreased risk. Both class I and class II genes have been studied. “This is a very interesting area that is gaining a lot of momentum,” Dr. Palefsky commented.

Also of heightened interest among researchers is the risk of dysplasia and carcinoma among the different HPV variants, most notably within the E6 and E7 oncogenes. These genes are known to modulate the cellular regulation processes that are essential for cell cycle progression and DNA replication, through interactions with the tumor suppressing genes pRB and p53. “Then again,” Dr. Palefsky said, “the variations in the proteins encoded by these variant genes may have nothing whatsoever to do with their interaction with p53 or pRB, but rather on the ability of the variant peptides to bind to MHC. Thus, a change in a particularly important immunodominant peptide might affect the ability of an HPV-infected person to defend against a particular HPV genotype.”

Prevalence of Cervical HPV, Dysplasia, and Carcinoma in HIV-Positive Women

SINCE HIV AND HPV ARE TRANSMITTED IN SOMEWHAT SIMILAR FASHION, the prevalence of HPV and cervical dysplasia among HIV-infected women would be expected to be relatively high. Data from the Women’s Interagency HIV Study (WIHS) suggest that this is true.

With respect to cervical HPV infection, Dr. Palefsky and his colleagues employed PCR to check for HPV in cervicovaginal lavage fluid collected from 2015 HIV-infected women and 577 HIV-negative controls (matched for age, drug use, and number of sexual partners) (Palefsky, 1999). Evidence of HPV infection was found in 58% of the HIV-positive women, compared with 26% of the controls.

HIV-positive women participating in the WIHS were also more likely to be infected with multiple HPV types. Approximately 42% of the HIV-positive women, compared with 16% of the HIV-negative controls, had evidence of more than one type of HPV in lavage samples. Almost one-quarter of the HIV-positive women were infected with three or more types of HPV.

Also of interest was an association between HPV infection, CD4+ cell counts, and HIV-RNA levels in the HIV-positive women. As the CD4+ cell count declined, a greater percentage of HIV-positive women were found to have HPV: approximately 45% of women with CD4+ counts >500 cells/mm³, 55% of women with CD4+ counts between 200 and 500 cells/mm³, and 70% of women with CD4+ counts <200 cells/mm³ had PCR evidence of HPV infection (see Figure 2). As for viral load, 71% of HIV-infected women with CD4+ counts above 500 cells/mm³ and plasma HIV-RNA levels in excess of 100,000 copies/mL were found to be positive for HPV, compared to 44% of HIV-positive women with similarly high CD4+ cell counts and less than 44,000 HIV-RNA copies/mL.

The WIHS has also demonstrated that HIV-infected women are more likely to have abnormal cervical cytology results (Massad, 1999). An analy-

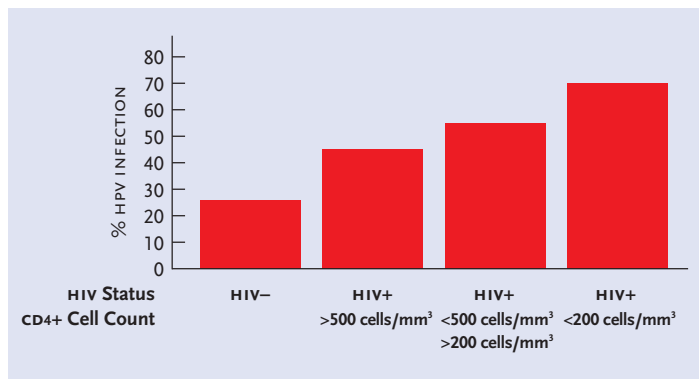


FIGURE 2. HPV in cervicovaginal lavage fluid collected from 2015 HIV-infected women and 577 HIV-negative controls participating in the Women’s Interagency HIV Study (WIHS). Illustrated here is the association between HPV infection and CD4+ cell counts in the HIV-positive women. As the CD4+ cell count declined, a greater percentage of HIV-positive women were found to have HPV: approximately 45% of women with CD4+ counts >500 cells/mm³, 55% of women with CD4+ counts between 200 and 500 cells/mm³, and 70% of women with CD4+ counts <200 cells/mm³ had PCR evidence of HPV infection.

Source: Palefsky JM, Minkhoff H, Kalish LA, et al. Cervicovaginal human papillomavirus infection in human immunodeficiency virus-1 positive and high risk HIV-negative women. *J Natl Cancer Inst* 91:226-39, 1999.

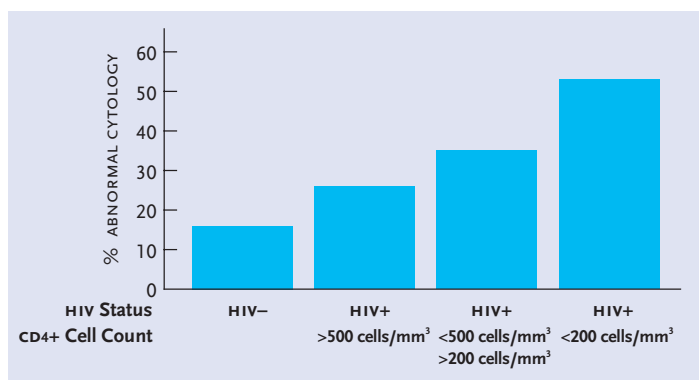


FIGURE 3. An analysis of Pap smears collected from 2054 HIV-positive women and 568 HIV-negative controls participating in the WIHS yielded a 40% overall prevalence of any type of abnormal Pap result (including ASCUS) in HIV-positive women, compared with an abnormal cytology rate of 17% among risk-matched HIV-negative controls. As with rates of HPV infection, rates of abnormal cytology corresponded with CD4+ cell counts in the HIV-positive women: approximately 26% of women with CD4+ counts >500 cells/mm³, 35% of women with CD4+ counts between 200 and 500 cells/mm³, and 53% of women with CD4+ counts <200 cells/mm³ had abnormal Pap results.

Source: Massad LS, Riestler KA, Anastos KM, et al. Prevalence and predictors of squamous cell abnormalities in Papanicolaou smears from women infected with HIV-1. *J Acquir Imm Defic Syndr Hum Retrovirol* 21:22-41, 1999.

sis of Pap smears collected from 2054 HIV-positive women and 568 HIV-negative controls yielded a 40% overall prevalence of any type of abnormal Pap result (including ASCUS) in HIV-positive women, compared with an abnormal cytology rate of 17% among risk-matched HIV-negative controls. As with rates of HPV infection, rates of abnormal cytology corresponded with CD4+ cell counts in the HIV-positive women: approximately 26% of women with CD4+ counts >500 cells/mm³, 35% of women with CD4+ counts between 200 and 500 cells/mm³, and 53% of women with CD4+ counts <200 cells/mm³ had abnormal Pap results (see Figure 3).

While the U.S. Centers for Disease Control (CDC) expanded its case definition of AIDS to include invasive cervical cancer, there hasn't been much in the way of hard evidence to conclude that HIV/HPV-coinfection, either in the absence or presence of immune suppression, is associated with a higher risk of cervical cancer. As explained by Dr. Palefsky, rates of cervical cancer have actually increased in certain pockets of the United States and other developed nations. "In certain areas around the country, notably New York City, we have seen an increase in cervical cancer," he explained. "It tends to be in women who have a history of injection drug use, which suggests that the rates of cancer in this group of women may be higher because they've had limited access to primary medical care and, perhaps, haven't had regular Pap smears. The same picture is actually seen in parts of Europe, in populations of injection drug users, who do not have regular access to medical care."

The picture in resource-poor areas, such as Africa, paints a surprising picture. In many African nations, where access to care is perhaps even more limited and HIV is rampant, one would expect cervical cancer rates to be substantially higher among HIV-positive women. "But this isn't the case," Dr. Palefsky answered. "The reason for this likely relates to the long period of time it takes for high-grade dysplastic lesions to become cancerous. In most of these countries, we have not yet introduced widespread antiretroviral therapy; women are dying of the usual AIDS-related causes before they've had time to progress to invasive cancer. What this suggests is that we are potentially in for real trouble, with respect to cervical cancer, once antiretroviral treatment programs go into effect in populations where cervical cancer screening is not routinely performed."

Diagnosing CIN and HPV in HIV-Positive Women

BOTH THE CDC AND THE AGENCY FOR HEALTH CARE POLICY AND RESEARCH recommend that HIV-infected women have a complete gynecologic evaluation, including a Pap smear and pelvic exam, as part of their initial evaluation. As reiterated by Dr. Palefsky, a Pap smear should be obtained twice in the first year following an HIV diagnosis. If these results are normal, annual examinations are then indicated. However, more frequent Pap smears should be obtained from HIV-positive women with previous abnormal Pap smears (including ASCUS or low-grade lesions) and after treatment for cervical dysplasia. The American College of Obstetricians and Gynecologists recommends Pap smears every three to four months for the first year after treatment of precancerous cervical lesions, followed by Pap smears every six months.

As for colposcopy, the indications include any cytologic abnormality (including ASCUS and atypical glandular cells of undetermined significance [AGUS]); after treatment of cervical dysplasia; and perhaps as an initial screening tool in HIV-positive women with less than 200 CD4+ cells/mm.³ Biopsies should be obtained at the time of colposcopy to confirm cytologic abnormalities.

New to the diagnostic landscape is HPV reflex testing. It has been approved by the FDA for women over the age of 30 years and is acknowledged by groups like the American College of Obstetricians and Gynecologists and the American Cancer Society as a useful assay to document the presence of oncogenic HPV types in patients with ASCUS on Pap smears. For women who test positive for an oncogenic HPV type, follow-up colposcopy is recommended. For women who are negative for an oncogenic HPV type using HPV reflex testing, colposcopy is performed only if the abnormality persists or progresses. It is not yet clear how HPV testing should be used in HIV-positive women.

Treatment Considerations in HIV-Positive Women with CIN

WHILE LOW-GRADE DYSPLASIA GENERALLY DOES NOT REQUIRE TREATMENT, given that it typically does not progress to high-grade dysplasia or cervical cancer, women with HSIL require therapy. Loop electric excision, laser ablation, and cryotherapy are highly effective when the entire lesion and transformation zone can be seen by colposcopy and when there is an absence of endocervical involvement. For women who do not meet these criteria, cervical conization remains the gold standard.

Compared with HIV-negative women, in whom the risk of HSIL recurrence two years after specific therapy is between 5% and 10%, the recurrence rate in HIV-positive women is in the ballpark of 50% within 12 months after completion of therapy (Maiman, 1999). Thus, there is an urgent need for new treatments—and new treatment strategies—to reduce the recurrence of medium- and high-grade cervical dysplasia in HIV-infected women.

III. Anal Dysplasia and Carcinoma

BEFORE REVIEWING THE LATEST THINKING AND TRENDS IN ANAL DYSPLASIA and carcinoma research, Dr. Palefsky impressed upon PRN members attending his April 2004 lecture that the anus is a human sexual organ, not exclusively a male or female sexual organ. "For clinicians interested in sexually transmitted diseases, the anus is a dream piece of real estate," he joked. "Both men and women are engaging in anal sex and both men and women are at risk for anal dysplasia and carcinoma."

Prevalence of HPV, Anal Dysplasia, and Anal Cancer

ANAL CANCER IS FAIRLY RARE. ITS INCIDENCE IN THE GENERAL POPULATION is less than one per 100,000 people and is one-tenth the current rate of cervical cancer in the United States. However, when evaluating the incidence of anal cancer among specific populations, more startling numbers come into play. In a 1987 paper published in the *New England Journal of Medicine*, it was estimated that incidence of anal cancer among HIV-negative men who engage in receptive anal intercourse with other men was up to 35/100,000—a rate on a par with the incidence of cervical cancer before routine Pap smears were initiated in the 1940s (Daling, 1987).

Even more troubling is the incidence rate among HIV-positive men who have sex with men. During the late 1980s, the incidence of anal cancer among gay men with AIDS was reported to be twice that of men of the same age, race, and sexual orientation in the years before AIDS (1975 to 1979) (Goedert, 1998). In other words, the incidence of anal cancer may be more than 70 of every 100,000 HIV-infected men who have a history of receptive anal intercourse with other men. "Although this is an extremely crude approach to estimate the incidence of anal cancer among these men," Dr. Palefsky admitted, "we've come up with similar numbers using totally separate approaches and analyses."

In another study reviewed by Dr. Palefsky, investigators at the National Cancer Institute in Bethesda studied invasive and *in situ* anal cancers among 309,365 HIV-positive patients, 51,760 of whom were women (Frisch, 2000). The incidence rates of carcinoma in these patients were compared with expected cancer rates in the general population and reported as a relative risk. Shockingly, the relative risk of anal cancer was 163-fold higher among HIV-positive men under the age of 30, compared with age-matched men under the age of 30 in the general population; among HIV-positive women under the age of 30, there was a 134-fold increase in the relative risk of anal cancer. For HIV-positive individuals be-

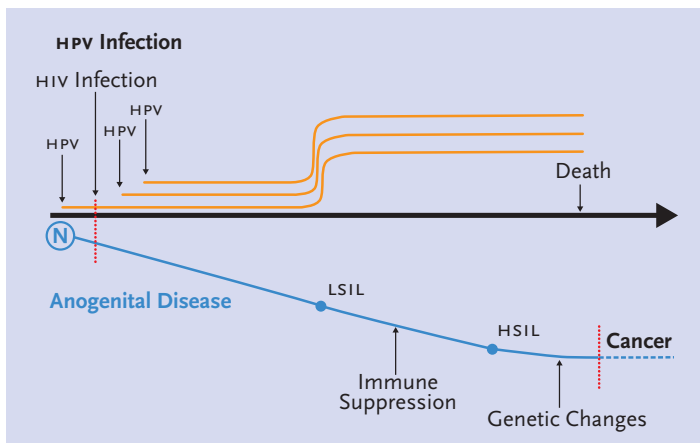


FIGURE 4. Pathogenesis of HPV-related anal squamous intraepithelial lesions (SIL) and anal cancer, before and after the introduction of antiretroviral therapy. HPV infection is likely acquired early after the onset of sexual activity. With more sexual activity, HIV infection becomes a risk, as does subsequent infections with different HPV types. During the early stages of HIV infection, HPV replication is kept in check. With advancing disease progression and immune suppression, there is an attenuation of HPV-specific immunity, resulting in increased HPV replication and, consequently, HSIL with genomic instability.

Source: Joel Palefsky, MD, FRCP(C)

tween the ages of 30 and 39, there was a 12.2-fold increase in the relative risk among women and a 40-fold increase among men. Among HIV-positive individuals 40 years of age and older, the relative risk of anal cancer was 2.6-fold higher for women and 32-fold higher for men. And looking at all HIV-positive patients as a whole, regardless of their age, the relative risk of 6.8-fold higher among women and 37-fold higher among men. Dr. Palefsky did caution, however, that these numbers can be misleading. “The reason that the numbers are so high in the under 30 group is that the incidence in the general population of people under the age of 30 is extremely low,” he explained. “As a result, just a handful of cases in HIV-positive people under the age of 30 would yield a startling relative risk fold change. So these numbers are a bit misleading, but they do underscore that the risk of anal cancer is higher among HIV-positive people.”

As with cervical dysplasia and cancer, anal HPV infection is a major risk factor for AIN and anal cancer. In one study published in 1998, Dr. Palefsky and his colleagues looked for anal HPV infection in 346 HIV-positive and 262 HIV-negative men who have sex with men (MSM) (Palefsky, 1998). Anal HPV-DNA was found in 93% of the HIV-positive men, compared with 61% of the HIV-negative men.

The spectrum of HPV types was similar in HIV-positive and HIV-negative men, with HPV-16 being the most common type. Infection with multiple HPV types was found in 73% of the HIV-positive men and 23% of the HIV-negative men.

Also of interest was an association between the presence of oncogenic HPV types and CD4+ cell counts. Nononcogenic HPV types (e.g., HPV-6; HPV-11) were documented with equal frequency in HIV-positive patients with less than 200 CD4+ cells/mm³, between 200 and 500 cells/mm³, or greater than 500 CD4+ cells/mm³. Oncogenic HPV types (e.g., HPV-16; HPV-18) were more common in patients with CD4+ counts below 200 cells/mm³ than in patients with greater than 500 CD4+ cells/mm³, a finding that was indicative of immune suppression being a significant cofactor in the replication of oncogenic, HSIL-causing HPV types.

Data from cross-sectional analyses involving women also paint a

grim picture. In one WHS analysis published by Dr. Palefsky and his colleagues, anal HPV infection was more frequent than cervical infection in both HIV-positive and high-risk HIV-negative women (Palefsky, 2001). One-hundred seventy of 223 (76%) HIV-positive women and 24/57 (42%) HIV-negative women had anal HPV infection detected by PCR. Among 200 women for whom there were concurrent anal and cervical HPV data, anal HPV was more common than cervical HPV in both HIV-positive (79% vs. 53%) and HIV-negative women (43% vs. 24%). Dr. Palefsky also reported that detection of HPV was inversely associated with CD4+ cell counts, but was not associated with plasma HIV-RNA levels.

With respect to high-grade AIN, disproportionately high rates have been documented in HIV-positive MSM. In one San Francisco cohort consisting of more than 600 MSM, LSIL and HSIL were present in 124/346 (36%) of HIV-positive men and 19/262 (7%) HIV-negative men (Palefsky, 1998a). The relative risk of AIN among HIV-positive men was inversely correlated with CD4+ cell count, when compared with HIV-negative men. For those with a CD4+ count greater than 500 cells/mm³, the relative risk was 3.8; for those with a CD4+ count between 200 and 500 cells/mm³, the relative risk was 5.6; and for those with a CD4+ count less than 200 cells/mm³, the relative risk was 7.3.

Natural History of HSIL and Cancer

AS FOR THE NATURAL HISTORY OF AIN IN GAY AND BISEXUAL MEN, PROSPECTIVE studies conducted in Seattle and San Francisco have yielded interesting results. In the Seattle cohort, 158 HIV-positive and 147 HIV-negative MSM without initial evidence of anal SIL were monitored for an average of 21 months (Critchlow, 1995). In less than two years, HSIL developed in 24/158 (15%) of the HIV-positive men and 8/147 (5%) HIV-negative men.

In a study evaluating the natural history of HSIL in another of Dr. Palefsky’s San Francisco cohorts, 277 HIV-positive MSM and 221 HIV-negative MSM—all of whom entered the study with either normal anal Pap test results, ASCUS, or LSIL—were followed prospectively for approximately four years (Palefsky, 1998b). During this period, 49% of the HIV-infected men developed HSIL, compared with 17% of the HIV-negative men. What’s more, HIV-positive men with either low-grade dysplasia or ASCUS at baseline were more likely to develop HSIL during the four years of follow-up, compared with HIV-positive men with normal anal Paps upon entering the study (57% vs. 38% respectively). As for HIV-positive men with ASCUS or LSIL at baseline, 33% developed HSIL during the four years of follow-up, compared with 14% of HIV-negative men who entered the study with ASCUS or LSIL.

As for progression to anal cancer, no study has actually been conducted to prove that anal HSIL leads to anal cancer. However, it requires little more than common sense to conclude that HSIL represents the true precursor lesion to anal cancer, based on what is already known about cervical HSIL and its association with cervical cancer. This assumption is based on a number of factors, including the histologic similarities between anal and cervical cancer and the observation that, like cervical cancer, anal cancer is often found with overlying HSIL. What’s more, Dr. Palefsky has personally seen patients with anal HSIL progress to cancer and pointed out that approximately 5% of patients with Bowen’s disease—perianal HSIL—involve lesions that undergo malignant changes.

At the same time, research has not been able to determine if HIV-positive men or women with AIN progress to anal cancer faster than their HIV-negative counterparts. However, as has been determined in the various epidemiological studies reviewed above, it is clear that HIV-positive men and women are at greater risk for anal cancer, given the highly disproportionate incidence and prevalence rates of HSIL.

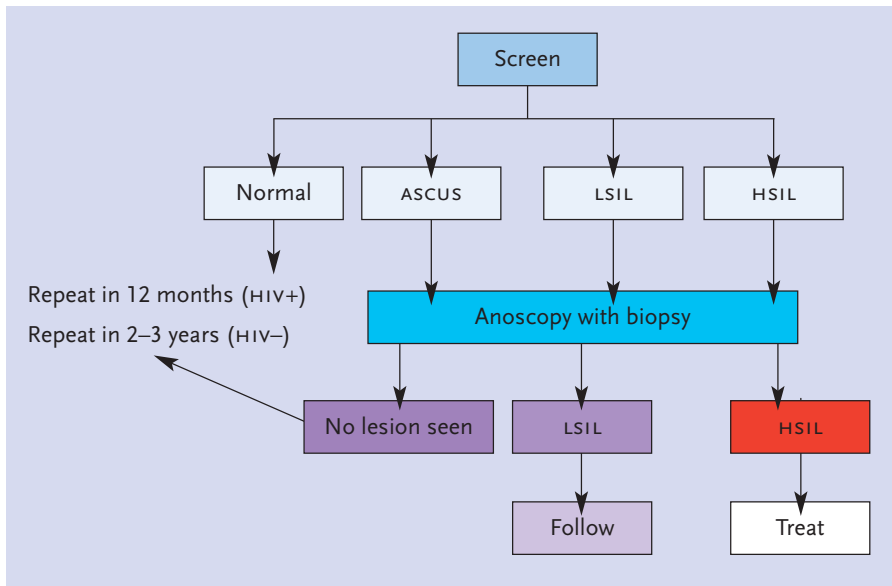


FIGURE 5. Anal Cytology Screening for Anal SIL In Men Who Have Sex with Men

While routine anal cytology screening has not been standardized by the United States Public Health Service (including the U.S. Centers for Disease Control), there is growing evidence to suggest that an anal screening program should be incorporated into the care of all at-risk individuals (e.g., men with a history of anal intercourse with other men [regardless of HIV serostatus], all HIV-positive men and women, and all women with high-grade cervical or vulvar lesions or cancer). At the time of the initial screening, if the cytology is normal, it is recommended that an anal Pap smear be repeated annually for HIV-positive men, and every two to three years for HIV-negative men. In the event of abnormal Pap findings—whether it be ASCUS, LSIL, or HSIL—high-resolution anoscopy with biopsy should be performed. ASCUS: atypical squamous cells of undetermined significance; LSIL: low-grade squamous intraepithelial lesions; HSIL: high-grade squamous intraepithelial lesions.

Source: Joel Palefsky, MD, FRCP(C)

Natural History and Pathogenesis of AIN in the Era of Antiretroviral Therapy

SINCE COMBINATION ANTIRETROVIRAL THERAPY BECAME THE STANDARD treatment approach in the mid-1990s, there has been a dramatic decline in the number of AIDS-related opportunistic infections and cancers, including Kaposi's sarcoma and lymphoma. When it comes to both cervical and anal cancer, however, incidence rates have remained largely unchanged.

The failure of antiretroviral therapy to decrease the incidence of AIN or progression of existing AIN—if confirmed in ongoing studies—could spell trouble in terms of future incidence rates of anal cancer. Before antiretroviral therapy went into widespread use, most HIV-infected patients typically died of classic AIDS-related complications and were simply not living long enough for high-grade dysplasia to advance to carcinoma. Today, with extended AIDS-free survival, the slow progression from high-grade dysplasia to carcinoma can potentially run its course.

Consistent with this theory are data from the California Cancer Registry, evaluating the incidence of anal cancer in California between 1973 and 1999 (Cress, 2003). Although the published analysis did not factor in HIV infection and antiretroviral use, the Registry did note a continued increase in the incidence of anal cancer among white and Hispanic men in San Francisco between 1995 and 1999, years in which combination antiretroviral therapy was gaining in use. Data are also available from a prospective study involving 28 HIV-positive MSM who had

high-grade dysplasia at the time of initiating antiretroviral therapy (Palefsky, 2000). Cytology and biopsy tests conducted six months later found that 16 (57%) had no change in their dysplasia, six (21%) regressed to low-grade dysplasia, five (18%) to ASCUS, and one (4%) had normal cytology. However, 4/30 (13%) men with low-grade dysplasia at baseline went on to develop high-grade disease within six months after initiating antiretroviral therapy.

As is illustrated in Figure 4, HPV infection is likely acquired early after the onset of sexual activity. With more sexual activity, HIV infection becomes a risk, as does subsequent infections with different HPV types. During the early stages of HIV infection, HPV replication is kept in check. With advancing disease progression and immune suppression, there is an attenuation of HPV-specific immunity, resulting in increased HPV replication and, consequently, HSIL.

The fact that improved immune function, attributed to antiretroviral therapy, does not appear to have an effect on HSIL regression or carcinoma risk, Dr. Palefsky and others believe that other biological factors are at play. One possibility is that the immune response, once HSIL has been established, fails to eliminate epithelial cells expressing HPV proteins. The consequence is sustained high-level expression of HPV proteins, such as E6 and E7 (discussed above), that lead to genomic instability. In other words, Dr. Palefsky theorizes that HSIL and the risk of cancer may be a one-way street: once lesions have accumulated sufficient genetic damage as a result of immune suppression, no amount of immune reconstitution can rectify the problem.

Screening Issues

THERE IS NO DENYING THAT CERVICAL PAP SMEAR AND COLPOSCOPE screenings have had a profound effect on the incidence of cervical cancer, among both HIV-positive and HIV-negative women. If we are to assume that anal dysplasia is similar to cervical dysplasia in its natural history and pathogenesis, compounded by the seemingly high prevalence and incidence of HSIL in certain populations, the suggestion that anal cytology screenings may play an invaluable role in detecting high-grade dysplastic lesions is merited.

In proposed guidelines published by Dr. Palefsky and his colleagues in 1997, it was recommended that all MSM undergo regular anal cytologies, regardless of HIV infection status (see Figure 5). Other groups who should be considered for screening include: women with cervical cancer or high-grade vulvar disease/cancer; all HIV-positive men and women, regardless of sexual orientation; individuals with perianal condyloma acuminata; and transplant recipients.

The first component of screening for anal HSIL is anal cytology or the Pap smear, colloquially referred to as “tush Paps.” As was published in the September 2001 *Notebook* review of HPV, Dr. Palefsky suggested that the sensitivity of anal Pap smears to detect abnormal cytology was approximately 80% in HIV-positive men and 51% in HIV-negative men, roughly similar to the accuracy of cervical Pap smears in HIV-positive and HIV-negative women. However, anal Pap smears often yield incorrect results regarding the grade of anal dysplasia present: lesions that are

concluded to be of a low-grade variety upon conducting a Pap smear may actually be high-grade upon conducting high-resolution anoscopy and biopsy.

To conduct an anal Pap smear, a Dacron swab is inserted into the anal canal. “When I’m telling people how to do Pap smears,” Dr. Palefsky recalled, “I tell them to push it up as far as it will go. Some papers in the literature say push it up two or three centimeters, but I think that’s wrong. You want to be sure to get rectal cells, which would indicate that the swab passed the transformation zone.” Additionally, Dr. Palefsky urges the use of Dacron swabs, not cotton swabs, and cotton tends to cling to the cells and won’t give them up for cytology. The swab should be moistened with water, not lubricant, as this may reduce the cellular yield of the sample.

Dr. Palefsky also pointed out that it’s also important to do a digital-rectal exam (DRE), but only *after* a Pap smear has been performed. “DRES may lead to detecting a cancer beneath the surface, which might be missed if visualization of the anal canal through the anoscope is the only diagnostic procedure,” he said. “However, DRES requires using lubrication and it’s important not to have lubrication in the anus when doing a Pap smear. In turn, it’s very important that the Pap smear be done first, followed by the DRE.”

In the event of abnormal Pap findings, high-resolution anoscopy should be performed. To visualize the anal wall, a disposable anoscope is used. As explained by Dr. Palefsky, it is inserted through the anal canal using a water-based lubricant. A swab, wrapped in gauze and soaked in 3% acetic acid, is then passed through the anoscope. The anoscope is then removed, leaving the acetic acid-soaked swab in the anus, pressed up against the anal epithelia, for approximately one minute. The swab is then removed and the anoscope reinserted. A colposcope is then brought to the opening of the anoscope to conduct the visual inspection.

Whereas healthy epithelial tissue inside the anus is pink and shiny, the application of acetic acid will turn dysplastic lesions dull and white (see Figure 6). These should be inspected and a biopsy should be taken. Another dye that can be used is Lugol’s solution. When taken up by healthy epithelial tissue, it will render the anal wall a deep mahogany color. Conversely, dysplastic lesions do not fully absorb this iodine-rich solution and will likely turn a mustard or light yellow color. These, too, should be examined and biopsied for staging purposes.

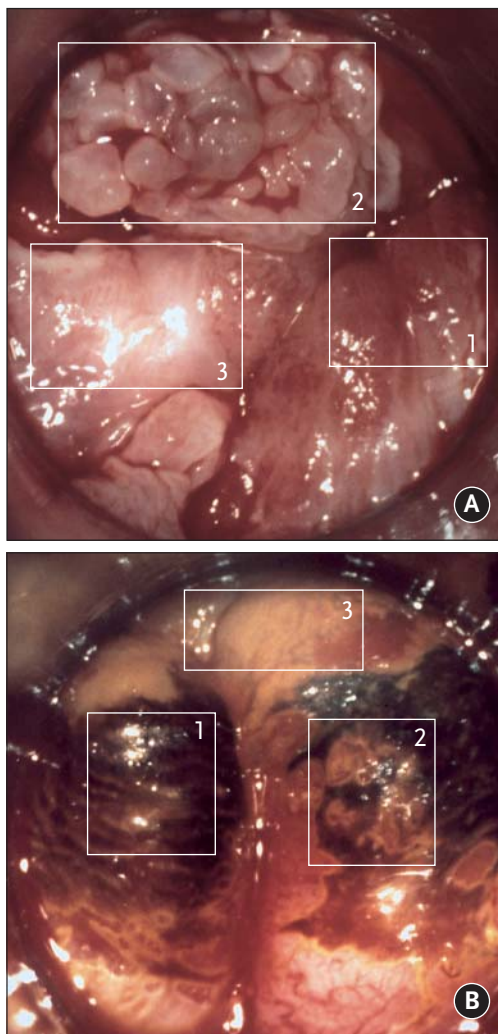


FIGURE 6. Images of Anal SIL

Images taken during high-resolution anoscopy (HRA) after applying 3% acetic acid. Areas of acetowhiteness correlate with higher nuclear density; a mild acetowhite epithelium correlates with less severe disease, whereas intensely acetowhite epithelium correlates with more advanced forms of SIL.

A) Healthy epithelial tissue appears pink and shiny [area 1]; a cluster of condylomas [area 2]; a thick acetowhite flat HSIL plaque within the squamocolumnar junction [area 3]. While the condylomas would likely have been felt upon digital examination, the HSIL lesion would have been missed without HRA and application of acetic acid.

B) Epithelium coated with acetic acid and Lugol’s iodine solution. Healthy epithelial tissue is dubbed Lugol’s positive and appears mahogany/black in color [area 1]; Lugol’s iodine solution is not fully absorbed by areas of low-grade dysplasia (Lugol’s positive LSIL) and appears dark yellow/mustard in color [area 2]; high-grade dysplastic lesions of the epithelium absorb very little Lugol’s iodine solution (Lugol’s negative HSIL) and appear white or light yellow [area 3].

Source: Stephen E. Goldstone, MD

As for anal warts found during visual inspection of the anus and anal wall, Dr. Palefsky pointed out that, in some cases, condylomas may contain high-grade lesions and should be biopsied and/or removed.

With that said, Dr. Palefsky discussed the elements of an anal screening program that should be incorporated into the care of all gay and bisexual men. At the time of the initial screening, if the cytology is normal, it is recommended that an anal Pap smear be repeated annually for HIV-positive men, and every two to three years for HIV-negative men. If the patient is found to have LSIL, routine follow-up should occur every six to 12 months without necessitating therapy. However, Dr. Palefsky pointed out that there is also a rationale to treat patients with LSIL if it can be done with minimal morbidity, since some of these lesions may progress to HSIL over time and because some patients prefer to have the lesions removed. As with cervical lesions, patients with HSIL should routinely receive therapy.

Treating Anal Dysplasia

THERE ARE A NUMBER OF ELEMENTS THAT GO into a successful screening and treatment program. The first is to pinpoint high-risk patients, which includes those discussed above. There is also a need for a greater number of clinicians who are capable of performing anal cytology screenings, clinicians who are capable of performing high-resolution anoscopy and biopsy, and pathologists trained to read cervical and anal cytology and histopathology. Dr. Palefsky also stressed the importance of office-based treatment. “At this point,” he said, “almost all of our patients are treated in the office. You don’t want to be doing diagnostic procedures if you can’t follow up with treatment. Learning how to do these treatments is not difficult. But where treatment is difficult, we have the need for surgeons.”

The principle behind treating condylomas is to provide symptomatic relief to patients. Condylomas can cause itching and burning, are unsightly and psychologically troubling for many people, and can result in the spread of HPV to someone else who comes into contact with the warts.

Dr. Palefsky pointed out that some condylomas resolve spontaneously, thereby eliminating the need for any type of therapy. When therapy is deemed necessary or is requested by the patients, home-applied medications are available for external warts if the patient recognizes them and knows where to apply the medication. Home-based options include:

imiquimod (Aldara), a cream that is applied to external lesions three times weekly, and podophyllotoxin (Condylox), a gel applied in cycles of three days on/four days off. “The problem I have with home-based therapies is that application can be difficult,” he said. “Unless a patient has a partner who is willing and able to directly apply the therapy, it may be difficult for patients to self-apply the medication unless they are using a mirror. And even then, there’s a possibility that they’ll miss little lesions or end up treating the wrong area.”

While home-based therapies may be suitable for some patients, Dr. Palefsky is partial to clinician-applied treatments. These include liquid nitrogen, 80% trichloroacetic acid (TCA), surgical excision, laser ablation, intralesional interferon, and infrared coagulation. “Infrared coagulation is a very nice treatment,” he added. “It involves applying a thermal probe to the surface of a lesion and using heat energy to remove it. The nice thing about it is that it was originally designed for the treatment of hemorrhoids, so it’s perfect for anal procedures.” He also explained that the heat wavelength coagulates blood vessels, resulting in very little bleeding and no smoke or vapor production.

The treatment of LSIL remains controversial. While LSIL is not considered to be a pre-cancerous lesion, it can contain smaller high-grade lesions. “Most clinicians opt to follow patients with low-grade cervical or anal lesions closely, without treatment, given that some low-grade lesions resolve spontaneously and that they do not lead directly to cancer,” Dr. Palefsky said. “However, I prefer to treat them in the anal canal when feasible, especially when symptoms are present.”

As for HSIL, this should be treated whenever possible. The choice of treatment will depend on the number, location, and sizes of the lesions. Unfortunately, as with cervical lesions, a number of patients with high-grade anal lesions experience a recurrence or persistence of disease. In turn, the need to retreat HSIL is commonplace. “Much of the treatment I do involves applications of TCA,” Dr. Palefsky said. “Sometimes I’ll use infrared coagulation and, occasionally, I need to send patients to a surgeon for surgical excision.”

Despite his preference to treat HSIL, Dr. Palefsky notes that in many cases, treatment is not the best choice, given that the likelihood of any one individual developing anal cancer remains low. This is particularly the case when the lesion is so large or diffuse that it is unlikely that even the most aggressive treatment will be successful in removing the lesion. In this case, Dr. Palefsky recommends close follow-up of the patient to monitor for early progression to cancer.

Prevention Possibilities: HPV Vaccination

DEVELOPMENT OF NEUTRALIZING ANTIBODIES TO HPV INVOLVES PRESENTATION TO THE IMMUNE SYSTEM OF CONFORMATIONAL EPITOPES DISPLAYED ON VIRAL CAPSIDS COMPOSED OF L1 PROTEIN. Empty viral capsids, dubbed “virus-like particles,” are synthesized with the use of microbial or cellular expression systems. *In vitro*, vaccination with L1 virus-like particles derived from species-specific papillomaviruses neutralizes virus and, in animals, protects against the development of lesions. And in early clinical trials, HPV-16 L1 virus-like-particle vaccines were well tolerated and generated high levels of antibodies against HPV-16.


Large-scale clinical trials of HPV-16 virus-like particle vaccines are currently under way. One study, involving an HPV virus-like particle vaccine being developed by Merck, was reported two years ago in the *New England Journal of Medicine* (Koutsky, 2002). In this double-blind study, 2,392 young women—defined as females 16 to 23 years of age (none of whom were infected with HIV)—were randomized to receive three doses of placebo or HPV-16 virus-like particle vaccine (40 µg per dose), giv-

en at day 0, month 2, and month 6. Genital samples to test for HPV-16 DNA were obtained at enrollment, one month after the third vaccination, and every six months thereafter. The primary endpoint was persistent HPV-16 infection, defined as the detection of HPV-16 DNA in samples obtained at two or more visits. The primary analysis was limited to women who were negative for HPV-16 DNA and HPV-16 antibodies at enrollment and HPV-16 DNA at month 7.

Of the 2,392 women enrolled in the study, 1,194 received vaccine and 1,198 received placebo. Altogether, 1,533 women—64% of the study cohort—were included in the primary analysis. These women were followed for a median of 17.4 months after completion of the vaccination regimen.

The incidence of persistent HPV infection was 3.8 per 100 woman-years at risk in the placebo group and 0 per 100 woman-years at risk in the vaccine group (100% efficacy). Thus, all 41 cases of HPV-16 infection occurred in the placebo group, nine of whom went on to experience LSIL or HSIL. While there were no cases of HPV-16-related SIL among the women who received the vaccine, there were equal rates of non-HPV-16-related SIL in the vaccine and placebo recipients (22 in each group).

The incidence of adverse events was similar in the two groups and the most frequently reported side effect was pain at the injection site.

“This was a proof of concept study,” Dr. Palefsky pointed out. “And in this study, we saw 100% efficacy, which is really quite something. It’s safe to say that the proof of concept has definitely been validated and that we should eagerly await the results of larger and longer clinical trials.” 

References

- American Society of Cytopathology (ASC). NCI Bethesda System 2001. ASC: September, 2003. Accessed at: <http://www.cytopathology.org/NIH/>
- Cress RD, Holly EA. Incidence of anal cancer in California: increased incidence among men in San Francisco, 1973–1999. *Prev Med* 36(5):550-60, 2003.
- Critchlow CW, Surawicz CM, Holmes KK, et al. Prospective study of high grade anal squamous intraepithelial neoplasia in a cohort of homosexual men: Influence of HIV infection, immunosuppression and human papillomavirus infection. *AIDS* 9:1255-62, 1995.
- Daling JR, Weiss NS, Hislop TG, et al. Sexual practices, sexually transmitted diseases, and the incidence of anal cancer. *N Engl J Med* 317:973-7, 1987.
- Frisch M, Biggar RJ, Goedert JJ. Human papillomavirus-associated cancers in patients with human immunodeficiency virus infection and acquired immunodeficiency syndrome. *J Natl Cancer Inst* 92(18):1500-10, 2000.
- Goedert JJ, Cote TR, Virgo P, et al. Spectrum of AIDS-associated malignant disorders. *Lancet* 351:1833-9, 1998.
- Koutsky LA, Ault KA, Wheeler CM, et al. A controlled trial of human papillomavirus type 16 vaccine. *N Engl J Med* 347:1645-51, 2002.
- Maiman M, Watts DH, Andersen J, et al. Vaginal 5-fluorouracil for high-grade dysplasia in human immunodeficiency virus infection: a randomized trial. *Obstet Gynecol* 94: 954-61, 1999.
- Massad LS, Riester KA, Anastos KM, et al. Prevalence and predictors of squamous cell abnormalities in Papanicolaou smears from women infected with HIV-1. *J Acquir Imm Defic Syndr Hum Retroviro* 21:22-41, 1999.
- Palefsky JM, Holly EA, Ralston ML, et al. Prevalence and risk factors for anal human papillomavirus infection in human immunodeficiency virus (HIV)-positive and high-risk HIV-negative women. *J Infect Dis* 183:383-91, 2001.
- Palefsky JM. Anal squamous intraepithelial lesions in human immunodeficiency virus-positive men and women. *Semin Oncol* 27:471-9, 2000.
- Palefsky JM, Minkhoff H, Kalish LA, et al. Cervicovaginal human papillomavirus infection in human immunodeficiency virus-1 positive and high risk HIV-negative women. *J Natl Cancer Inst* 91:226-39, 1999.
- Palefsky JM, Holly EA, Ralston ML, et al. Prevalence and risk factors for human papillomavirus infection of the anal canal in human immunodeficiency virus (HIV)-positive and HIV-negative homosexual men. *J Infect Dis* 177(2):361-7, 1998.
- Palefsky JM, Holly EA, Ralston ML, et al. Anal squamous intraepithelial lesions in HIV-positive and HIV-negative homosexual and bisexual men: Prevalence and risk factors. *J Acquir Immune Defic Syndr Hum Retrovir* 17:320-6, 1998a.
- Palefsky JM, Holly EA, Ralston ML, et al. High incidence of anal high-grade squamous intraepithelial lesions among HIV-positive and HIV-negative homosexual/bisexual men. *AIDS* 12:495-503, 1998b.