Common Cutaneous Complications of HIV Disease

Jeffrey S. Roth, MD, PhD
Instructor, Department of Dermatology, Columbia University College of Physicians and Surgeons
Clinical Instructor, Department of Dermatology, Mount Sinai School of Medicine

Summary by Theo Smart; Robert Warner, MD; and James Braun, DO

From warts to scabies to malignancies, skin disorders "are more common and more aggressive in HIV-positive patients than others," Dr. Jeffrey Roth told members of PRN. Dr. Roth presented a slide-show overview on the clinical manifestation and diagnosis of the cutaneous complications of HIV disease (several of these slides are reproduced over the next few pages). At the same meeting, Dr. Charles Farthing reviewed the dermatologic procedures most useful for primary-care providers working with HIV-positive patients (see page 11).

Warts are the most common skin complaint of HIV-positive patients

Warts

The most common skin complaint of HIV-positive patients is warts. These dull-colored papules erupt anywhere on the skin, including the anal mucous membrane, vagina, scrotum, penis and mouth. Their appearance, size and number vary with the site. Warts can range in size from less than 1 mm to 1-2 cm "cauliflower lesions."

Warts are dull-colored papules that erupt anywhere on the skin, including the anal mucous membrane, vagina, scrotum, penis and mouth

The smaller lesions often can be treated locally with podophillum resin of varying strengths, trichlorocetic acid, and/or liquid nitrogen. Larger lesions generally require surgical debridement or excision, at least as a first step. Lasers have been used, even though it is unclear whether they represent an advance over other physically destructive modalities. Two other treatments, Condylox topical solution (podofilox 0.5%) and Aldara cream (imiquimod 5%) can be used at home, as can 5FU. The success with these modalities appears to be more limited, especially in patients with more advanced immunosuppression. "Warts can be difficult to eradicate in HIV-positive people, and the larger and more multiple the warts, the worse the prognosis for ultimate eradication. This seems to be a special defect in immune competence."

Dr. Roth recommends biopsying most warts—particularly when multiple or very large—on initial presentation to determine their cancer risk. Caused by the human papillomavirus (HPV), warts are grouped by subtype: strains 6 and 11; 16 and 18; or 31, 33, and 35. The three groups differ from one another in oncogenic potential. The oncogenic strains, particularly 16 and 18, are probably the major cause of cervical carcinoma in women and rectal carcinoma in both men and women. "Biopsying provides useful information in terms of patient management and assessing the danger for the patient's sex partner," said Dr. Roth. Above all, a biopsy is necessary to make certain that what looks like a wart is a wart—and not a squamous cell carcinoma with metastatic potential. Such carcinomas are sometimes mislabeled as multiply resistant, or recalcitrant, warts, and in a worst-case scenario if untreated on the penis, amputation may eventually be required.

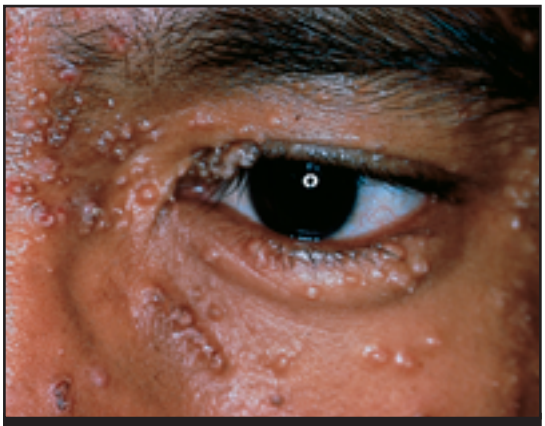

Molluscum contagiosum may be very widely distributed, especially on the face and neck. Papules tend to be dome-shaped and to have a certain translucence

Molluscum Contagiosum

Molluscum contagiosum is almost as prevalent as warts. In people with AIDS, molluscum may be very widely distributed, especially on the face and neck, and much more difficult to control. Molluscum can be distinguished from warts by several features. Molluscum papules tend to be dome-shaped and to have a certain translucence. In better-developed lesions, there is often an umbilication. Histologically, the papules contain protein and viral particles known as molluscum bodies. Unlike warts, molluscum, which are caused by a pox virus, do not occur in the mouth or anorectal mucosa and have no known oncogenic potential.

Like warts, molluscum may spread and can be transmitted to other people through direct contact. Dr. Roth reported seeing "many cases of multiple warts and molluscum spread through razor blades. I tell patients that if they are going to shave their bodies, use a different razor from the one they use for their face. I advise a patient to use an electric razor or to change his razor every time he shaves, or if he can't do that, to clean the razor in alcohol, hydrogen peroxide or some other disinfectant solution, or under hot water. Otherwise, this practice can quickly lead to a carpet of molluscum or warts in the pubic area or on the face." He further cautioned that a condition called cutaneous cryptococcus may be mistaken for molluscum. Early cryptococcus lesions may present as dome-shaped papules with umbilication, although as they advance, more necrotizing features become evident. "Don't be afraid that every molluscum you see is actually cryptococcus," he said. "Cryptococcus is much, much more unusual." Cases of severely resistant molluscum, unusual lesions or cases in which systemic signs are present should be biopsied with appropriate stains to rule out cryptococcosis.

Folliculitis

The "itchy, red bumps" HIV-positive patients bewail are likely the swollen papules of folliculitis, which can appear anywhere on the skin. Dr. Roth considers the condition's usual name—eosinophilic folliculitis—inaccurate; he prefers atypical folliculitis, since it can have a variety of causes. "If you biopsy the folliculitis, you may find no distinguishing features whatsoever," he explained. "On occasion you will find an overgrowth of pityrosporum-type yeasts, Demodex mites or other microorganisms. I suspect that many cases of atypical folliculitis represent a hypersensitivity reaction to normal microscopic residents of human skin." Accordingly, he recommends that therapy target the problem-causing microorganism. "Eurax (crotamiton) works well in some cases, antifungals or Flagyl (metronidazole) in others," he said. Though its effects are only temporary, ultraviolet B radiation has proved useful, as has Accutane, an anti-acne retinoid that makes the chemical environment of the sebaceous gland less hospitable to the microorganism.

Atypical folliculitis may represent a hypersensitivity reaction to normal microscopic residents of human skin

Seborrheic Dermatitis, Psoriasis and Tinea

Seborrheic dermatitis, psoriasis and tinea are often confused with one another. Seborrheic dermatitis is another condition that appears to occur more frequently in HIV disease. Characterized by erythema and rounded, itchy, scaly plaques on the scalp, the face and occasionally the chest and groin, seborrheic dermatitis is thought to be caused by a hypersensitivity reaction to fungi in hair follicles. It is usually a chronic condition that can be controlled with hydrocortisone or ketoconazole cream.

Psoriasis also produces erythema and plaques that can occur in any location. These plaques, which tend to be covered with silvery scales, typically do not itch and may, in fact, bleed when scratched. But beware: Psoriasis is not exclusively a cosmetic problem. It can cause arthritis in the joints and extremely debilitating lesions on the hand or foot. Traditional therapies do not work very well in HIV-positive patients, and topical steroids lose their effectiveness quickly. Some success has been reported with etretinate (Tegison), a relative of Accutane, or PUVA (ultraviolet A light after pretreatment with psoralen). Dovonex cream (calcipotriene 0.005%) has had success, especially in intretriginous and genital psoriasis. Tazarotene gel, a new retinoid, is another potential treatment for HIV-associated psoriasis.

Tinea tend to have an advancing edge, or "active border," with central clearing. Scrapings are positive on KOH examination. Tinea may be treated with topical antifungals, but in more severe cases oral antifungals may be needed as well.

Nail problems—particularly psoriasis and fungal infections—trouble many patients with HIV. Psoriasis may cause pits in, or complete dystrophy of, the nail—a notable diagnostic characteristic when the skin findings are equivocal on KOH exam. Fungal-infection scrapings from these nails would be positive. However, because a traumatized nail is more vulnerable to fungi than one intact, psoriatic nails are often co-

infected with tinea, yeasts or aspergillus. This may be demonstrated by culture.

Scabies

The mite *Sarcoptes scabiei* can erupt on the wrists, folds of the skin, webs between the fingers and even, in people with HIV, on the face or scalp. Its itchy, red papules are sometimes mistaken for folliculitis, but the patient's foremost complaint will be itchiness. Visual cues that can help the clinician identify scabies are the linear furrows interspersed with papules (see photo on page 14). There can also be a vesicular component secondary to a hypersensitivity reaction. A more severe variant, Norwegian scabies, properly termed hyperkeratotic scabies, forms large crusted plaques that may resemble psoriasis.

An immune-competent individual hosts, on average, ten to 20 scabies-causing mites. "The two live in a sort of immunologically mediated harmony," Dr. Roth said. "But in a person with HIV, the number of mites can jump to the hundreds, thousands or even tens of thousands. This in turn introduces into a sexually active community a pool of mites much larger than it had been before epidemic immunodeficiency." Clinicians should take care when touching these lesions during diagnosis lest they catch scabies. The use of latex gloves and hand washing at the end of examination cannot be overemphasized.

Lindane (Kwell) is inexpensive, but relatively ineffective for the treatment of Norwegian scabies. Therefore, the treatment of choice is Elimite (5% permethrin) — this seems to be ovicidal as well as scabicidal. Future developments may include approval of ivermectin, a single-dose oral agent which has been shown to erradicate epidemic scabies in human populations (this product currently is approved for veterinary use).

Herpesviruses

Breakouts of grouped blister-like lesions typically caused by the common herpes simplex virus are easily recognized. In people with advanced HIV, however, these may develop into chronic ulcers and fissures with a substantial degree of edema. These erosions may occur on the oral and genital mucosa as well as perianally; their scalloped edge is the hallmark for diagnosis. A culture is helpful, but HSV IgG levels are generally not, as the commercial tests for HSV antibodies do not reliably distinguish between types 1 and 2. Since HSV-1 infection is endemic in the North American population, this is likely to contribute little. HSV IgM levels may help in culture-negative, otherwise confusing cases. Dr. Roth said that a Tzanck smear is usually reliable in experienced hands.

In contrast to herpes simplex, zoster is dermatomal. Although it is widely believed that the vesicles of zoster are larger than herpes,' Dr. Roth contends that is not always the case. Zoster's dermatomal pattern may be so vague as to make diagnosis difficult, but this, too, he says, is unusual. Prodermal pain following a dermatomal pattern can be an important diagnostic clue before or during the earliest stages of vesiculation. Chronic zoster may present as hyperkeratotic dermatomal nodules.

A zoster infection is considered "disseminated" when it contains more than 20 nondermatomal lesions or involves the eye. A patient with zoster-involving V1, the ophthalmic division of the trigeminal nerve, should be immediatedly referred to an ophthalmologist due to the risk of corneal ulceration. Signs or symptoms of this condition such as painful vesicular lesions on the tip of the nose or lid margins should be considered an ocular emergency. A significant number of people with HIV disease may also develop Herpes meningoencephalitis secondary to disseminated zoster. Neurological symptoms should be sought and a mental status exam should be included in the neurological exam of patients presenting with shingles. If present, a neurological consultation with a lumbar puncture is imperative, and intravenous acyclovir is indicated.

Uncomplicated zoster outbreaks should be treated with acyclovir (Zovirax) 800 mg five times a day or famciclovir (Famvir) 500 mg three times a day, both for ten days.

Large crusted plaques caused by Norwegian scabies can be confused with psoriasis.

In immune deficiency, the number of scabies can jump dramatically and cause a therapeutic challenge.

Zoster (shingles) is dermatomal.

Other Skin Infections

Cutaneous *Staphylococcus aureus* infections can cause impetigo—pustules with a honey-colored crust—blisters or folliculitis on the face or trunk. Neglected infections can progress to ecthyma. Like molluscum, staphylococcus bacteria can be spread by shaving and are highly contagious from person to person. Since the foci of staphylococcus colonization is in the nares or perianal region, "HIV-positive patients subject to recurrent infections may benefit from

Bacillary angiomatosis, a vascular proliferation that resembles KS

an antibiotic ointment such as Bactroban (mupirocin) twice a day in the nose and around the anus to keep the staph carriage to a minimum," Dr. Roth recommended.

Patients alarmed at a lesion that resembles Kaposi's sarcoma may instead have bacillary angiomatosis, a vascular proliferation that resembles KS. The causative agent, *Bartonella henslae,* can be observed upon biopsy. Nodular melanoma may also need to be considered in the differential diagnosis.

Malignancies

Dr. Roth closed by reminding PRN members that in addition to KS (see Dr. Krown's review on page 2) they should be cautious not to overlook non-AIDS-related skin malignancies in people with HIV. The most common include basal cell carcinomas, which have a pearly, rolled border; squamous cell carcinomas that occur perianally following oncogenic wart infection; and malignant melanomas, pigmented lesions characterized by their large size, asymmetry and irregular colors or borders. "It's important to avoid tunnel vision in just looking for infectious complications of HIV," he said, emphasizing that a melanoma may kill a patient much faster than HIV disease. ●

Bibliography

Ansary MA, Hira SK, Bayley AC, et al. *A Colour Atlas of AIDS in the Tropics.* London, Wolfe Medical Publications, 1989.

Farthing CF, Brown SE, Staughton RCD, et al. *Color Atlas of AIDS and HIV Disease.* Chicago, Year Book Medical Publishers, 1988.

Friedman-Kien AE, *Color Atlas of AIDS.* Philadelphia, W.B. Saunders, 1989.

Grossman ME, Roth J. *Cutaneous Manifestations of Infection in the Immunocompromised Host.* Baltimore, Wilkins & Wilkins, 1995.

Lipman MCI, Gluck TA, Johnson MA. *An Atlas of Differential Diagnosis in HIV Disease.* New York, London, Parthenon Publishing, 1995.

Ray MC and Gately LE. **Dermatologic manifestations of HIV infection and AIDS.** *Infectious Disease Clinics of North America* September 1994;8:583-605.

Zalla MJ, Su WPD, Fransway AF. **Dermatologic manifestations of human immunodeficiency virus infection.** *Mayo Clin Proc* November 1992;67:1089-1108.

N O T E S